




Blood ozonization in patients with mild to moderate COVID-19 pneumonia: a single centre experience

Carlo Tascini¹ · Giovanni Sermann² · Alberto Pagotto¹ · Emanuela Sozio^{1,3} · Chiara De Carlo¹ · Alessandro Giacinta¹ · Francesco Sbrana⁴  · Andrea Ripoli⁵ · Nadia Castaldo¹ · Maria Merelli¹ · Barbara Cadeo¹ · Cristiana Macor² · Amato De Monte²

Received: 13 July 2020 / Accepted: 14 October 2020
© Società Italiana di Medicina Interna (SIMI) 2020

Abstract

The emerging outbreak of the coronavirus disease 2019 (COVID-19) caused by the severe acute respiratory syndrome coronavirus 2 (SARS-CoV-2) continues to spread worldwide. We prescribed some promising medication to our patients with mild to moderate pneumonia due to SARS-CoV-2, however such drugs as chloroquine, hydroxychloroquine, azithromycin, antivirals (lopinavir/ritonavir, darunavir/cobicistat) and immunomodulating agents (steroids, tocilizumab) were not confirmed as effective against SARS-CoV2. We, therefore, started to use auto-hemotherapy treated with an oxygen/ozone (O₂/O₃) gaseous mixture as adjuvant therapy. In Udine University Hospital (Italy) we performed a case–control study involving hospitalized adult patients with confirmed COVID-19 with mild to moderate pneumonia. Clinical presentations are based upon clinical phenotypes identified by the Italian Society of Emergency and Urgency Medicine (SIMEU—Società Italiana di Medicina di Emergenza-Urgenza) and patients that met criteria of phenotypes 2 to 4 were treated with best available therapy (BAT), with or without O₃-autohemotherapy. 60 patients were enrolled in the study: 30 patients treated with BAT and O₂/O₃ mixture, as adjuvant therapy and 30 controls treated with BAT only. In the group treated with O₃-autohemotherapy plus BAT, patients were younger but with more severe clinical phenotypes. A decrease of SIMEU clinical phenotypes was observed (2.70 ± 0.67 vs. 2.35 ± 0.88 , $p = 0.002$) in all patients during hospitalization but this clinical improvement was statistically significant only in O₃-treated patients (2.87 ± 0.78 vs. 2.27 ± 0.83 , $p < 0.001$), differently to the control group (2.53 ± 0.51 vs. 2.43 ± 0.93 , $p = 0.522$). No adverse events were observed associated with the application of O₂/O₃ gaseous mixture. O₂/O₃ therapy as adjuvant therapy could be useful in mild to moderate pneumonia due to SARS-CoV-2. Randomized prospective study is ongoing [ClinicalTrials.gov ID: Z7C2CA5837].

Keywords COVID-19 · SARS-CoV-2 · Cytokine release syndrome (CRS) · Medical O₃ · O₃ therapy · O₃ gas · Autotransfusion · Oxidative stress · Reactive oxidative species · Lipid ozonation products

Introduction

The emerging outbreak of the coronavirus disease 2019 (COVID-19) caused by the severe acute respiratory syndrome coronavirus 2 (SARS-CoV-2) continues to spread worldwide. According to the COVID-19 situation report published by the World Health Organization (WHO), a total

of 14.3483858 confirmed cases and 603.691 deaths have been identified globally up to July 20th 2020 [1].

The full spectrum of COVID-19 ranges from mild, self-limiting respiratory tract illness to severe progressive pneumonia, multi-organ failure, and death [2].

There is a reasonable hypothesis that after a first viral phase with low severity illness, there could be a host immune response with variable lymphopenia, and an inflammatory cytokines release syndrome (CRS) which would play an important role in severe COVID-19 cases, leading to worsening acute respiratory failure [3].

In this context of CRS, patients could take advantage of O₃ gas anti-inflammatory and immune-modulatory properties. On this basis, we performed a case–control study in

✉ Carlo Tascini
c.tascini@gmail.com

✉ Francesco Sbrana
francesco.sbrana@ftgm.it

Extended author information available on the last page of the article

patients with COVID-19 to assess O₃-autohemotherapy as adjuvant therapy, in addition to the prescription of standard treatments used such as hydroxy-chloroquine, azithromycin, antivirals (lopinavir/ritonavir, darunavir/cobicistat) and immunomodulating agents (steroids, tocilizumab) [4, 5].

O₂/O₃ mixture, a gas discovered in the mid-nineteenth century, is a molecule consisting of three atoms of oxygen in a dynamically unstable structure due to the presence of mesomeric states [6].

Although O₃ gas has dangerous effects when inhaled, some reports on O₃ therapeutic effects have been documented.

Since the First World War, blood ozonization has shown an effective bacterial effect. Furthermore, the diffusion of several studies regarding patient infected by Ebola and treated with O₃ therapy demonstrate its capacity to stimulate oxygen metabolism and to modulate the immune system. During the First World War (1914–1918), doctors familiar with O₃ antibacterial properties, and with few other medical resources available, applied it topically to infected wounds, thus revealing O₃ hemodynamic and anti-inflammatory properties [6–8].

O₃ therapy administration depends on treatment goals and location of therapy: it has been administered intravenously, intramuscular, into body cavities (rectum, bladder, and vagina), joints, subcutaneous and soft tissues, intraperitoneally, and even intrathecally [9]. However, the first and most popular application is O₃ autohemotherapy (O₃-AHT) which requires a predetermined blood sample (100–200 mL) to be drawn and thus, using stoichiometric calculations, a precise concentration of O₂-O₃ can be infused. This small amount of blood is subjected to O₂-O₃ ex-vivo and is then administered to the patients [10].

O₃ has many further demonstrated mechanisms of action:

- (1) Increase of red blood cell 2,3 di-glycerophosphate (greater hemoglobin oxygen release);
- (2) Modulation of endothelial nitric oxide production;
- (3) Induction of a greater arterial/venous partial pressure difference, indicating greater mitochondrial consumption of oxygen (energy production);
- (4) Modulation of the immune system and reduction of inflammation,
- (5) Improvement of antioxidant status, antioxidant enzymes (including superoxide dismutase), and glutathione in cells [9];

In vitro O₃ interferes with virus-to-cell contact in lipid-enveloped viruses via oxidation of lipoproteins, proteins, and glycoproteins, thus interfering with the viral reproductive cycles [10].

O₃ in the blood reacts with plasma antioxidant and gives rise to several messengers, among them H₂O₂, that readily

diffuses into immune cells. Moreover, O₃ acts as a regulator in signal transduction, facilitating several immune responses [11, 12].

Another important effect of O₃-AHT in the COVID-19 therapeutic context is the down-regulation action of pyrin domain-containing protein 3 (NLRP3) inflammasome, which is known to play a crucial part in the initiation and continuance of inflammation in various diseases [13].

The rationale of blood ozonization is to evaluate the additive anti-inflammatory and immunomodulatory action mediated by O₃ in patients hospitalized for SARS-CoV-2.

Methods

Study patients

Male and non-pregnant female patients 18 years of age or older were eligible if they had a diagnostic specimen that was positive to RT-PCR for SARS-CoV2 and pneumonia confirmed by chest imaging. All patients gave their informed consent to participate in the study. Exclusion criteria were pregnancy, G6PHD (glucose 6 phosphate dehydrogenase) deficiency, concomitant serious diseases and failure to obtain informed consent.

This study was approved by the Friuli Venezia Giulia ethics committee (Protocol n° Z7C2CA5837).

The full spectrum of COVID-19 ranges from mild, self-limiting respiratory tract illness to severe progressive pneumonia, multi-organ failure, and death. The Italian Society of Emergency and Urgency Medicine (SIMEU—Società Italiana di Medicina di Emergenza-Urgenza) suggests to classify the COVID-19 patients in 5 clinical phenotypes [14]:

- *Phenotype 1*: subjects with fever and without respiratory failure (normal Arterial Blood Gas analysis—ABG-, six-minute walking test—6mWT—and Chest XR). These patients can usually manage at home maintaining a quarantine period.
- *Phenotype 2*: subjects with fever but with ABG and/or Chest XR indicative of modest respiratory insufficiency (PO₂ > 60 mmHg in ambient air) and/or pulmonary consolidation area. These patients need to be hospitalized because they can worsen quickly.
- *Phenotype 3*: subjects with fever associated with moderate-severe respiratory insufficiency (at triage PO₂ < 60 mmHg in ambient air) and/or bilateral pulmonary consolidation area at Chest XR. These patients need to be treated with high flow oxygen therapy.
- *Phenotype 4*: subjects with respiratory failure with suspected ARDS (Adult Respiratory Distress Syndrome) or complicated pneumonia. These patients require hospitalization in a sub-intensive care unit.

- *Phenotype 5*: subjects suffering from ARDS initially. These patients will require Intensive Care Unit (ICU) admission and non-invasive positive pressure ventilation (NIPPV) or mechanical ventilation.

In the present study, we enrolled subjects with modest to moderate respiratory insufficiency (SIMEU clinical phenotypes 2–4) hospitalized in an infectious disease ward.

For all patients were recorded age, gender, presence of obesity, Charlson comorbidity index, delta time from symptoms onset to hospital admission, hospital length of stay, and symptoms (fever, dry cough, dyspnea, syncope, myalgia, asthenia, diarrhea, hypo/dysgeusia, hypo/anosmia).

The other best available therapy (BAT) administered included: antiretroviral therapy (lopinavir/ritonavir 2 tablets every 12 h, darunavir/cobicistat 1 tablet per day), hidrossy-cloroquine 400 mg every 12 h than the first day, followed by 200 mg every 12 h for other 4 days, tocilizumab *iv* 10 mg/kg in single dose, amiodarone, azithromycin, other antibiotics and steroids.

The endpoints of the study were: SIMEU clinical phenotypes at admission and discharge, delta classes SIMEU (negative values mean clinical improvements), admission to Intensive Care Unit (ICU) and death. Blood gas analysis (BGA) parameters were recorded at admission. Furthermore, baseline value of White Blood Cells (WBC), lymphocytes count, platelets, CPK, LDH and IL-6 blood level were reported.

Medical ozone (O₃) procedure

The systemic O₃ treatment procedure was decided by the physician on duty and started first at the patient's bedside with the drawing of autologous blood and, after proper O₂/O₃ mixing, with its re-infusion. After inserting a catheter in the patient's vein which was connected to a latex-free plastic bag, containing 35 ml of sodium citrate, a blood amount of 200 ml was drawn from the patient. At the end, the withdrawal line was washed and re-used to infuse saline solution. The blood, without any patient disconnection, was then mixed with a gas mixture of a 200 ml composed by 96% O₂ and 4% O₃, with a O₃ therapeutic range of 40 µg/mL of gas per mL blood. To guarantee the O₂/O₃ homogeneous diffusion into the blood, the bag was gently mixed for about 10 min, subsequently, the blood was re-infused into the patient. O₃ treatment lasted for 3 consecutive days.

Outcome

The end-point was the time of respiratory improvement and earlier weaning from oxygen support: these parameters were included in the SIMEU clinical phenotypes classification.

Statistical analyses

All variables were reported as mean ± standard deviation, median and interquartile interval or proportion, depending on their distribution. Accordingly, comparisons between treated and controls were performed with independent samples two-tailed *t* test, Mann–Whitney test or chi-squared test with continuity correction. Mixed ANOVA was used to compare the SIMEU class values, cross-classified by treatment and time (before and after treatment). Paired sample's *t* test was used when appropriate. For analyses, the R statistical software was used [15].

Results

A total of 60 patients were enrolled in the study: 30 with O₃-AHT as adjuvant therapy added to BAT and 30 controls treated with BAT only. Among the 30 patients treated with O₃-AHT (cases group), 28 received three consecutive O₃-AHT sections, and 2 received two consecutive doses.

Table 1 shows the baseline demographic and clinical characteristics of the 60 patients enrolled in the study. The control group treated with BAT only were older and with more co-morbidities than the other group. Instead, patients treated with O₃-AHT as adjuvant therapy had a more serious clinical respiratory condition with lower PaO₂/FiO₂ and SpO₂/FiO₂ ratio and lower lymphocytes count.

Notably, SIMEU clinical phenotypes at hospital admission were slightly higher in O₃-treated patients, meaning that their conditions were more severe, even if the difference was not fully statistically significant (2.87 ± 0.78 vs. 2.53 ± 0.51 , $p = 0.054$).

In general, a decrease of SIMEU clinical phenotypes was observed (2.70 ± 0.67 vs. 2.35 ± 0.88 , $p = 0.002$) in overall population during hospitalization. However, this clinical improvement was statistically significant only in O₃-treated patients (2.87 ± 0.78 vs. 2.27 ± 0.83 , $p < 0.001$) and not in the control group (2.53 ± 0.51 vs. 2.43 ± 0.93 , $p = 0.522$).

Figure 1 shows the clinical improvement (in green) in the two groups, in O₃ group there was a 53% improvement with respect to 33% of the control group. In the group with O₃-AHT adjuvant therapy, only 7% of patients had a worse outcome, compared with 17% in the control group.

Figure 2 shows all the 30 patients treated with O₃-AHT adjuvant therapy, according to the improvement of SIMEU clinical phenotypes and the time of O₃-AHT therapy; 26 out of 30 patients were treated in the first 5 days after hospital admission. Four patients (two for each group) were intubated, and only two patients died in the control group.

Given the nature of this preliminary study, data on a limited number of laboratory measures were collected. No adverse events were recorded in both patients' arms.

Table 1 Comparison of clinical characteristics of patients treated with blood ozonization vs. controls

	Overall patients (n = 60)	Blood ozonization group (n = 30)	Control group (n = 30)	p
Male	41 (68%)	23 (77%)	18 (60%)	0.267
Age (years)	61 ± 13	57 ± 12	65 ± 13	0.0148
Charlson Comorbidity Index	2 [1–3]	1 [0–3]	2 [1–4]	0.0445
Obesity	7 (12%)	3 (10%)	4 (13%)	1
Δ time symptoms—hospital admissions (days)	7 [5–9]	7 [5–8]	7 [5–9]	0.9345
Hospital stay (days)	9.37 ± 4.63	9.37 ± 3.84	9.37 ± 5.38	1
Fever	58 (97%)	30 (100%)	28 (93%)	0.472
Cough	33 (55%)	21 (70%)	12 (40%)	0.0379
Dyspnoea	30 (50%)	17 (57%)	13 (43%)	0.4386
Syncope	3 (5%)	1 (3%)	2 (7%)	1
Myalgia	7 (12%)	4 (13%)	3 (10%)	1
Asthenia	32 (53%)	20 (67%)	12 (40%)	0.0701
Diarrhoea	13 (22%)	6 (20%)	7 (23%)	1
Hypo/dysgeusia	22 (37%)	13 (43%)	9 (30%)	0.4216
Hypo/anosmia	18 (30%)	9 (30%)	9 (30%)	1
Antiretroviral therapy	59 (98%)	30 (100%)	29 (97%)	1
Tocilizumab therapy	21 (35%)	12 (40%)	9 (30%)	0.5883
Amiodarone	2 (3%)	1 (3%)	1 (3%)	1
Azithromycin	20 (33%)	11 (37%)	9 (30%)	0.7842
Other antibiotics	19 (32%)	12 (40%)	7 (23%)	0.267
Systemic steroids	2 (3%)	1 (3%)	1 (3%)	1
Clinical SIMEU Class—Admission	2.7 ± 0.67	2.87 ± 0.78	2.53 ± 0.51	0.0545
Clinical SIMEU Class—Discharge	2.35 ± 0.88	2.27 ± 0.83	2.43 ± 0.94	0.4678
Δ Clinical SIMEU Class	0 [– 1–0]	– 1 [– 1–0]	0 [– 1–0]	0.0436
Clinical worsening	7 (12%)	2 (7%)	5 (17%)	0.4212
ICU admission for IOT	4 (7%)	2 (7%)	2 (7%)	1
Death	2 (3%)	0 (0%)	2 (7%)	0.472
BGA—Admission				
PaO ₂ (mmHg)	74.1 ± 19.9	71.8 ± 17.0	76.4 ± 22.5	0.3681
FiO ₂ (%)	25.7 ± 8.6	27.6 ± 9.3	23.7 ± 7.6	0.0753
PaO ₂ /FiO ₂ ratio	307 ± 101	277 ± 87	336 ± 107	0.0234
O ₂ Saturation	96.4 ± 2.6	96.4 ± 2.3	96.4 ± 2.8	0.9601
SpO ₂ /FiO ₂ ratio	403 ± 87	377 ± 93	429 ± 75	0.0202
WBC (/mmc)	5.61 ± 2.57	5.57 ± 2.43	5.65 ± 2.75	0.9049
Lymphocytes (/mmc)	0.91 ± 0.3	0.83 ± 0.3	0.98 ± 0.3	0.0497
Platelets (/mmc)	196.8 ± 82.3	213.5 ± 102.6	180.1 ± 51.7	0.1187
LDH (U/L)	616 ± 253	675 ± 278	558 ± 213	0.0711
C reactive protein (mg/L)	75.7 [38.1–118.8]	76.4 [45.5–122.3]	67.6 [26.2–107.7]	0.3711
CK (U/L)	100 [64–193]	105 [71–201]	93 [61–155]	0.5242
IL-6 (pg/ml)	36.5 [20.0–68.3]	44.[21–58]	33.0 [20.0–78.0]	0.7947

BGA blood gasses analysis, CK creatine, FiO₂ fraction of inspired oxygen, ICU intensive care unit, IL-6 interleukin-6 (normal range: <7 pg/ml), IOT tracheal intubation, LDH lactate dehydrogenase, PaO₂ arterial oxygen tension, WBC white bloods cells, time from symptoms onset to hospital admission/clinical SIMEU classchange, respectively

Discussion

This preliminary report describes the clinical outcomes in a small group of patients with COVID-19 who were moderately ill (SIMEU clinical phenotypes 2–4) and were

treated with BAT plus O₃-AHT with respect to BAT alone. Specifically, clinical improvement status was observed in 53% of the patients in the O₃ group and 33% in the control group; instead, the clinical stability was observed in 40% of O₃-AHT group and in 50% in the control group, failure was

Fig. 1 Comparison of clinical classes in subjects treated with blood ozonation compared to controls

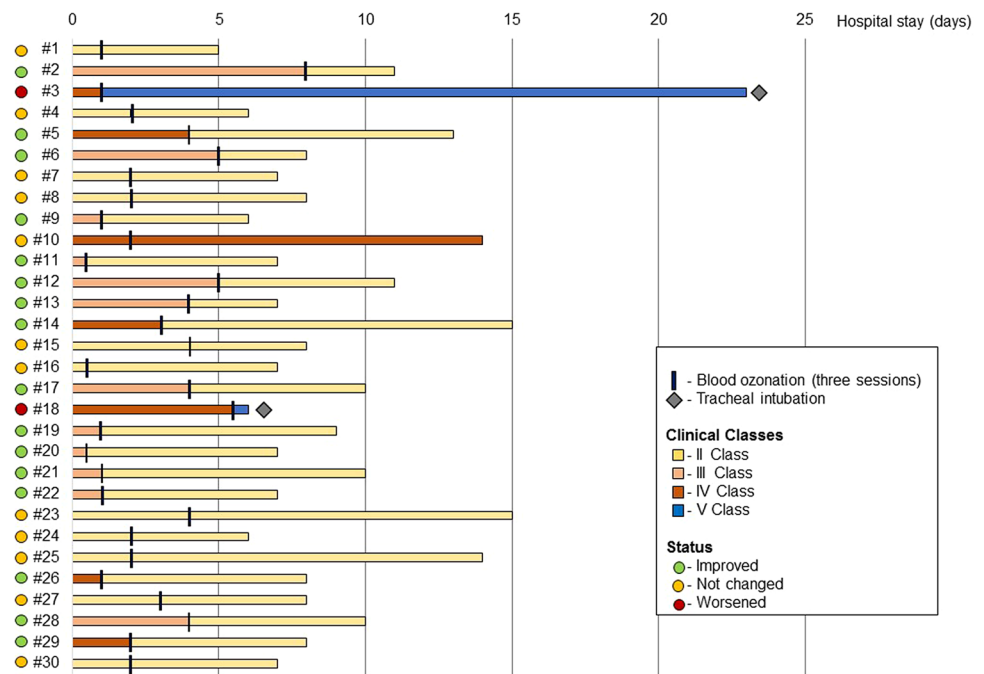
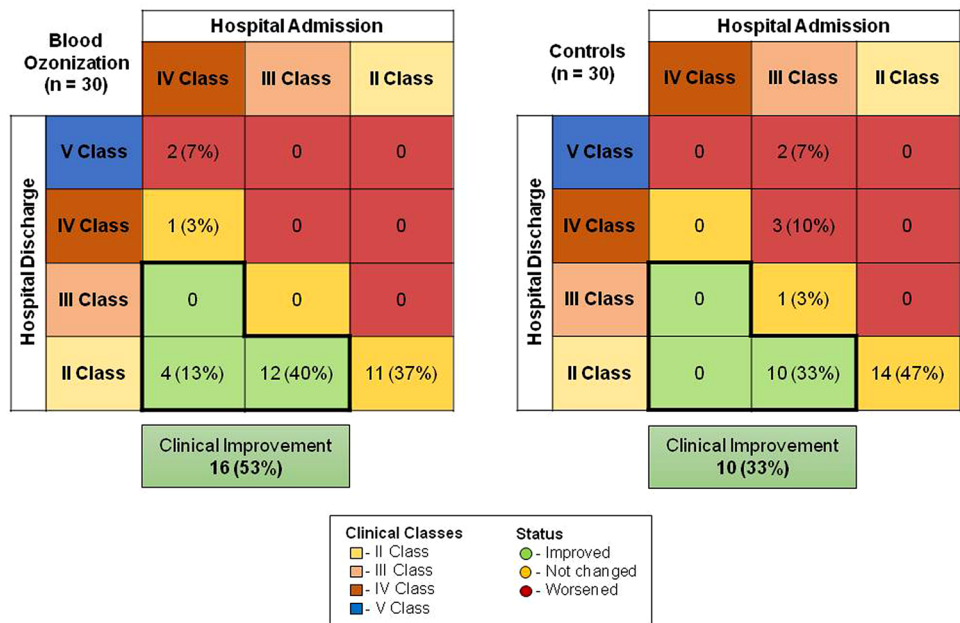


Fig. 2 Change in clinical classes before and after blood ozonization during the hospital stay



observed in 7% of O₃-AHT group with respect to 17% of the control group. Mortality was observed in only two cases in the control group: the low rate of mortality may be due to the patients' profiles enrolled in the study with mild or moderate cases of pneumonia due to SARS-CoV-2.

Case fatality Rate (CFR) in Friuli Venezia Giulia was 0.3% at July 20th 2020 while in Italy CFR was 14.3% [16], however, mortality was very different across the regions and wards of admission [17–19]. This mortality rate in

our patients with mild to moderate pneumonia was not surprising.

None of the patients enrolled in the study were intubated at the moment of the inclusion, whereas at the end four patients were intubated, 2 for each group. In a recent study of compassionate use of remdesivir [20], 64% of patients were intubated at the baseline and mortality was 18%, instead in less severe cases, mortality was 5%, very similar to the value observed in our study.

To note that, respect to the World Health Organization guidance [21], that is based on clinical data and radiological data only for patients with ARDS and designed for clinicians caring COVID-19 patients during all phases of their disease (i.e. screening to discharge), the SIMEU clinical phenotypes [14] use both clinical and radiological criteria for all patients, allowing a better patients stratification during the first phase of the disease, especially in the field of emergency medicine and might be more precise in patients stratification during the follow-up. This classification might be more useful for evaluating the clinical and radiological improvement of patients included in a clinical trial on COVID-19.

Although several limitations, the present study suggests that the clinical effectiveness of O₂/O₃ therapy in addition to the standard of care ensured at Udine University Hospital in patients with mild to moderate COVID-19 pneumonia. The O₃-AHT therapy is based on oxidative preconditioning [22] that leads to the reduction of IL-6 and IL-1b [23]. This effect can explain a cytoprotective action observed during O₃-AHT therapy. Furthermore, O₃-AHT therapy has been used in viral infection (Ebola, Influenza and HIV) with preliminary good results [10, 24].

Unfortunately, our study did not collect viral load data to confirm the anti-viral effects of O₂/O₃ therapy.

No adverse events were detected during O₃-AHT therapy, neither haemolysis or local vein damages.

Interpretation of the results of this study is limited because of the small size of the enrolled group, the short duration of follow-up, the potential missing data due to the retrospective nature of this study, and the lack of a randomization.

Although the latter precludes definitive conclusions, comparisons with contemporaneous cohorts from the literature suggest that O₂/O₃ therapy may have a clinical benefit in patients with mild to moderate COVID-19 pneumonia.

Physicians desperately need therapy for COVID-19. Published case reports might support inexpensive O₂/O₃ utility for infectious disease management, not only for microbicidal activity but also for the immunomodulation activity. O₃ (and other oxidation) therapy carries virtually no known adverse or toxic effects when performed properly (other than sporadic vein issues, as can other intravenous therapies).

Me (C.T.) has never administered O₃-AHT therapy before COVID-19, and the discussion with the anaesthesiologist (A.D.M.) brought us to try a therapy with few adverse effects for an infection without any available therapy. O₂/O₃ is not the panacea for all diseases, however, evidence-based medicine strongly suggests that randomized prospective studies are necessary. On this basis, according to the ethical committee of Region Friuli Venezia Giulia, Italy, we started a multicentre prospective randomized study of therapy with BAT with or without O₃-AHT adjuvant therapy for mild to

moderate pneumonia due to COVID-19. The study is currently ongoing [Clinical Trials.gov ID: Z7C2CA5837].

Acknowledgements The authors thank Dr.Laura Sabatino for helpful English editing.

Author contribution GS, ADM: protocol design, patient care and manuscript preparation; FS, ES, AR: protocol design, manuscript preparation; AP, CDC, AG, NC, MM, BC, CM: protocol design and patient care; CT protocol design and manuscript preparation. All authors gave Manuscript final approval.

Funding No financial support was received.

Compliance with ethical standards

Conflict of interest C.T. has received funds for speaking at symposia organized on behalf of Pfizer, Novartis, Merck, Angelini, Zambon, Thermofischer, Biotest, Gilead, Hikma, Biomerieux and Astellas. All other authors: None.

Human and animal rights statement Patients and/or the public were not involved in the design, or conduct, or reporting or dissemination plans of this research.

Consent for publication Not required.


References

1. World Health Organization. Situation updates on July 20 2020. <https://www.who.int/emergencies/disease/novel-coronavirus-2019/situation-reports/>. Accessed 20 July 2020
2. Cao B, Wang Y, Wen D, Liu W, Wang J, Fan G, Ruan L, Song B, Cai Y, Wei M, Li X, Xia J, Chen N, Xiang J, Yu T, Bai T, Xie X, Zhang L, Li C, Yuan Y, Chen H, Li H, Huang H, Tu S, Gong F, Liu Y, Wei Y, Dong C, Zhou F, Gu X, Xu J, Liu Z, Zhang Y, Li H, Shang L, Wang K, Li K, Zhou X, Dong X, Qu Z, Lu S, Hu X, Ruan S, Luo S, Wu J, Peng L, Cheng F, Pan L, Zou J, Jia C, Wang J, Liu X, Wang S, Wu X, Ge Q, He J, Zhan H, Qiu F, Guo L, Huang C, Jaki T, Hayden FG, Horby PW, Zhang D, Wang C (2020) A trial of lopinavir-ritonavir in adults hospitalized with severe Covid-19. *N Engl J Med*. <https://doi.org/10.1056/NEJMoa2001282>
3. Zhang C, Wu Z, Li JW, Zhao H, Wang GQ (2020) The cytokine release syndrome (CRS) of severe COVID-19 and Interleukin-6 receptor (IL-6R) antagonist tocilizumab may be the key to reduce the mortality. *Int J Antimicrob Agents*. <https://doi.org/10.1016/j.ijantimicag.2020.105954>
4. Lu CC, Chen MY, Chang YL (2020) Potential therapeutic agents against COVID-19: what we know so far. *J Chin Med Assoc*. <https://doi.org/10.1097/JCMA.0000000000000318>
5. Fanin A, Calegari J, Beverina A et al (2020) Hydroxychloroquine and azithromycin as a treatment of COVID-19. *Intern Emerg Med* 15:841–843
6. Elvis AM, Ekta JS (2011) Ozone therapy: a clinical review. *J Nat Sci Biol Med* 2:66–70
7. Bocci AV (2006) Scientific and medical aspects of ozone therapy. *State of the art*. *Arch Med Res* 37:425–435
8. Bocci AV, Zanardi I, Travagli V (2011) Ozone acting on human blood yields a hormetic dose-resposne relationship. *J Transl Med* 9:66

9. Rowen RJ (2019) Ozone and oxidation therapies as a solution to the emerging crisis in infectious disease management: a review of current knowledge and experience. *Med Gas Res* 9:232–237
10. Smith NL, Wilson AL, Gandhi J, Vatsia S, Khan SA (2017) Ozone therapy: an overview of pharmacodynamics, current research, and clinical utility. *Med Gas Res* 7(3):212–219
11. Gulmen S, Kurtoglu T, Meteoglu I, Kaya S, Okutan H (2013) Ozone therapy as an adjunct to vancomycin enhances bacterial elimination in methicillin resistant *Staphylococcus aureus* mediastinitis. *J Surg Res* 185:64–69
12. Caliskan B, Guven A, Ozler M, Cayci T, Ozcan A, Bedir O, Surer I, Korkmaz A (2011) Ozone therapy prevents renal inflammation and fibrosis in a rat model of acute pyelonephritis. *Scand J Clin Lab Invest* 71:473–480
13. Ricevuti G, Franzini M, Valdenassi L (2020) Oxygen-ozone immunocutaneous therapy in COVID-19 outbreak: facts and figures. *Ozone Ther*. <https://doi.org/10.4081/ozone.2020.9014>
14. <https://www.simeu.it/w/articoli/leggiArticolo/3964/leggi>
15. R Core Team. R: a language and environment for statistical computing. Vienna, Austria. 2013. <https://www.R-project.org/>
16. <https://coronavirus.jhu.edu/data/mortality>
17. Grasselli G, Zangrillo A, Zanella A, Antonelli M, Cabrini L, Castelli A, Cereda D, Coluccello A, Foti G, Fumagalli R, Iotti G, Latronico N, Lorini L, Merler S, Natalini G, Piatti A, Ranieri MV, Scandroglio AM, Storti E, Cecconi M, Pesenti A, COVID-19 Lombardy ICU Network (2020) Baseline characteristics and outcomes of 1591 patients infected with SARS-CoV-2 admitted to ICUs of the Lombardy Region, Italy. *JAMA*. <https://doi.org/10.1001/jama.2020.5394>
18. Perlini S, Canevari F, Cortesi S et al (2020) Emergency department and out-of-hospital emergency system (112—AREU 118) integrated response to Coronavirus disease 2019 in a Northern Italy centre. *Intern Emerg Med* 15:825–833
19. Erika P, Andrea V, Cillis MG et al (2020) Triage decision-making at the time of COVID-19 infection: the Piacenza strategy. *Intern Emerg Med* 15:879–882
20. Grein J, Ohmagari N, Shin D, Diaz G, Asperges E, Castagna A, Feldt T, Green G, Green ML, Lescure FX, Nicastrì E, Oda R, Yokoi K, Quiros-Roldan E, Studemeister A, Redinski J, Ahmed S, Bennett J, Chelliah D, Chen D, Chihara S, Cohen SH, Cunningham J, D’Arminio Monforte A, Ismail S, Kato H, Lapadula G, L’Her E, Maeno T, Majumder S, Massari M, Mora-Rillo M, Mutoh Y, Nguyen D, Verweij E, Zoufaly A, Osinusi AO, DeZure A, Zhao Y, Zhong L, Chokkalingam A, Elboudwarej E, Telep L, Timbs L, Henne I, Sellers S, Cao H, Tan SK, Winterbourne L, Desai P, Mera R, Gaggari A, Myers RP, Brainard DM, Childs R, Flanagan T (2020) Compassionate use of remdesivir for patients with severe Covid-19. *N Engl J Med*. <https://doi.org/10.1056/NEJMoa2007016>
21. World Health Organization. Clinical management of COVID-19—interim guidance. <https://www.who.int/publications/i/item/clinical-management-of-covid-19>
22. Leon OS, Menendez S, Merino N, Castillo R, Sam S, Perez L, Cruz E, Bocci V (1998) Ozone oxidative preconditioning: a protection against cellular damage by free radicals. *Mediators Inflamm* 7:289–294
23. Clavo B, Rodriguez-Esparragon F, Rodriguez-Abreu D, Martinez-Sanchez G, Llontop P, Aguiar-Bujanda D, Fernandez-Perez L, Santana-Rodriguez N (2019) Modulation of oxidative stress by ozone therapy in the prevention and treatment of chemotherapy-induced toxicity: review and prospects. *Antioxidants (Basel)* 8:588
24. Rowen RJ, Robins H, Carew K, Kamara MM, Jalloh MI (2016) Rapid resolution of haemorrhagic fever (Ebola) in Sierra Leone with ozone therapy. *Afr J Infect Dis* 10:49–54

Publisher’s Note Springer Nature remains neutral with regard to jurisdictional claims in published maps and institutional affiliations.

Affiliations

Carlo Tascini¹ · Giovanni Sermann² · Alberto Pagotto¹ · Emanuela Sozio^{1,3} · Chiara De Carlo¹ · Alessandro Giacinta¹ · Francesco Sbrana⁴  · Andrea Ripoli⁵ · Nadia Castaldo¹ · Maria Merelli¹ · Barbara Cadeo¹ · Cristiana Macor² · Amato De Monte²

¹ U.O. Malattie Infettive, Dipartimento di Medicina dell’Università di Udine, Università di Udine e Azienda Sanitaria Universitaria Integrata di Udine, Via Pozzuolo, 330, 33100 Udine, Italy

² SOC Anestesia e Rianimazione Uno, Università di Udine e Azienda Sanitaria Universitaria Integrata di Udine, Via Pozzuolo, 330, 33100 Udine, Italy

³ Pronto Soccorso e Medicina d’urgenza / HDU Livorno, Azienda USL, Toscana Nord Ovest, 33100 Livorno, Italy

⁴ U.O. Lipoapheresis and Center for Inherited Dyslipidemias, Fondazione Toscana “Gabriele Monasterio”, Via Moruzzi, 1, 56124 Pisa, Italy

⁵ Deep Health Unit, Fondazione Toscana “Gabriele Monasterio”, Via Moruzzi, 1, 56124 Pisa, Italy